



PATIENT

Arvo Bowen

SPECIES

Canine

BREED

Corgi Mix

SEX

MN

AGE

6 y

WEIGHT

24.2 lb

PRESENTING CLINICAL SIGNS

New grade II/VI murmur.

ECHOCARDIOGRAPHIC FINDINGS

2D, M-mode, and Doppler study.

Left atrial size is normal. The mitral valve leaflets are mildly thickened, and a mild to moderate jet of mitral regurgitation is present. Left ventricular dimensions are normal. Left ventricular systolic function is hyperdynamic. The aorta and aortic valve are normal. Right atrial and right ventricular dimensions are normal. The tricuspid valve leaflets are mildly thickened, and a mild jet of tricuspid regurgitation is present. The pulmonary artery and pulmonic valve are normal. No shunting lesions are visualized. No heartworms are visualized. No pericardial effusion or cardiac masses are seen.

LA - 29.4 mm
LVIDd - 28.3 mm
LVIDs - 15.4 mm
FS - 45.6%
RA - 16.8 mm
LVOT - 0.94 m/s
RVOT - 0.54 m/s

INTERPRETED BY

Keith Blass, DVM, MS,
DACVIM (Cardiology)

IMAGING PERFORMED BY

Dr. Kicker

HOSPITAL NAME

Wauwatosa VC

REFERRING VET

Dr. Haynes

INVOICE

DATE

5/19/26

ASSESSMENT/RECOMMENDATIONS

Degenerative mitral and tricuspid valve disease - stage B1

This examination demonstrates regurgitation of blood across Arvo's mitral and tricuspid valves resulting from degenerative valve disease. The hemodynamic effects of the regurgitations appear to be mild at present, as Arvo does not have secondary dilation of any of his cardiac chambers, and his ventricular systolic function is well-preserved. As such, Arvo's current risk for the development of clinical signs secondary to his valvular diseases, such as coughing, exercise intolerance, syncope, labored breathing, and abdominal distension, appears to be low.

No therapy is recommended at this stage of Arvo's valvular diseases.

A recheck echocardiogram is recommended in 6 months to monitor for disease progression.



PATIENT

Arvo Bowen

SPECIES

Canine

BREED

Corgi Mix

SEX

MN

AGE

6 y

WEIGHT

24.2 lb

INTERPRETED BY

Keith Blass, DVM, MS,
DACVIM (Cardiology)

IMAGING PERFORMED BY

Dr. Kicker

HOSPITAL NAME

Wauwatosa VC

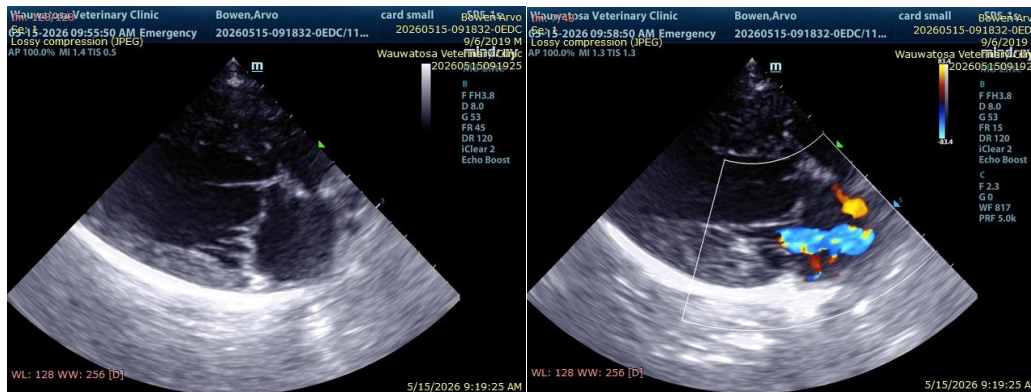
REFERRING VET

Dr. Haynes

INVOICE

DATE

5/19/26



The information and recommendations provided are based on the images presented by the referring veterinarian/sonographer. No evaluation can be communicated regarding pathology that was not visible in the image/video clips provided.

Thank you for this referral. If the clinical or image interpretation does not parallel your findings or if I can be of any further assistance please contact me.

Keith Blass, DVM, MS, DACVIM (Cardiology) info@SonoPath.com